

# RESCUING FELIX

*A Crippled and Disabled  
Wire Fox Terrier*



Felix has small features, a button nose & eyes that melt your soul. A large black heart shape saddle is displayed on his back, a sign he was destined to be saved & like all animals, deserves quality of life.



Felix had an under bite & his jaw appears crooked with some teeth out of place. His upper left canine has pierced a hole clear through his gum. He was in need of dental correction early, cleaning and most likely some extractions and his gums are infected. Felix was hungry and capable of gobbling up canned food and this was a good sign.

The single & only page received from his Arkansas vet reflected two visits - one in early 2011 for his neuter, vaccinations, blood work normal and healthy appearance. The teeth issue was noted, surgical correction recommended & seemed a minor issue at that time to correct but declined. The second visit was in May 2012 and the following was noted on exam & after sedation:

***Mouth is too painful to open; nails curled around, dirty hair balls hanging off of him, thick exudate buildup in medial canthi of eyes; penile prolapse?***

Felix was 3 years old when his owner from Arkansas decided it was time for him to leave. He was not bestowed with a fair shake in life or with his first home. He may have been born with birth defects but with no medical attention given for these birth defects and the neglect and confinement he suffered, they worsened creating a world of pain for this little Wire Fox boy. Felix arrived at Wire Fox Terrier Rescue Midwest on August 1, 2013. He is a true Wire Fox Terrier - strong willed and driven to survive and lives for having his ears rubbed and massaged. Felix was so happy to be rescued & wants to live and be loved.

*Removed hair balls that were embedded around upper incisors; the upper incisors that the lower canine tooth is going in between are needed to be extracted from severe root exposure; upper palate has been reformed by this canine tooth and think removing the incisors will improve his malocclusion problems; feels like an old mandibular rami fracture that healed incorrectly.*



Felix was not able to walk correctly or comfortably. On August 7, 2013 he was sedated and x-rays were taken of his legs, spine and mouth. He drags both back legs, the right more severe & nonfunctional. The right leg has no fibula, probably never formed and the patella dislocated. The rear left leg he drags but also uses to push off with. The muscle is tight, the tibia is bowed and patella is dislocated. There is also curvature of his spine. He is very determined, learned to adapt to his disabilities & does his best to survive. Heart breaking to watch him struggle.

Felix uses his front legs to bear the brunt of his weight and to get around and climb stairs often using his tail to balance. His upper back is enlarged and very tight.



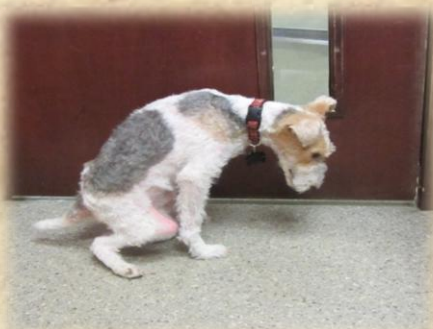The third and last vet visit was in October of 2012 for boarding only and Felix was in deplorable condition once again - filthy, matted, nails curled around and in pain.



On August 14, 2013 Felix went to Veterinary Specialty Center in Buffalo Grove, Illinois. He was examined & evaluated by Dr. Gendreau and admitted to the hospital. Felix would be sedated for an intense examination of the rear legs and further x-rays. A call from the surgeon with his diagnosis and would be performing surgery that evening on his left leg only.

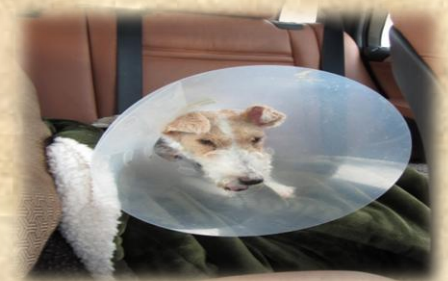
*Hemivertebrae Kyphosis which is curvature of the spine and related to his posture and hunchback. All of Felix's defects should have been tended to as a puppy & were correctable.*

*The right leg was diagnosed with lateral patella luxation - keeping the stifle joint in maximal flexion. Severe contracture of the hamstring muscles. The diagnosis for the right leg is beyond repair and the recommendation was to consider amputation of this leg in the future. The leg appears very red due to the skin stretching over his knee and bone extensively.*

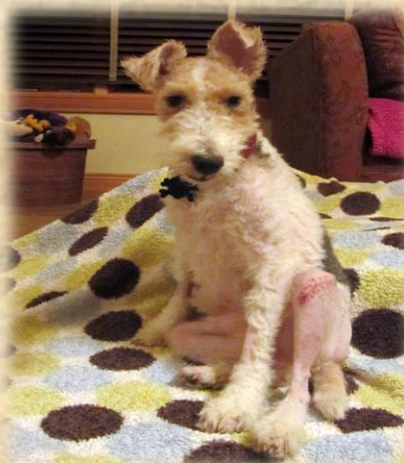
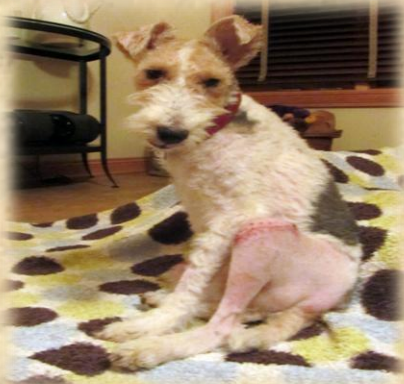
*The left leg was diagnosed with medial patella luxation - Grade IV - preventing normal extension of the stifle joint. The surgery performed was a Left TCT - Trochleoplasty (block recession trochleoplasty) and capsuloplasty. The bone was also twisted and the patella ridge was not there and rounded. His bone needed to be cut and turned for placement. There was excessive tissue on the outside which was then cut, grafted over his kneecap to the inside and doubled as a bandage.*

*The Diagnosis for Felix included Prognathism which is where the lower jaw extends longer than the upper which can cause dental misalignment as they age.*



Felix was released on August 15th only to head right back to the hospital later that evening. He was not eating or drinking and in a great deal of pain. The right leg deformity made it even more difficult for Felix. The pain medications were in pill form and he refused and did not want anyone to even approach him. Felix was panting and crying out. He went back to VSC for pain management, IV pain medications and fluids and also has a fentanyl patch and observation.

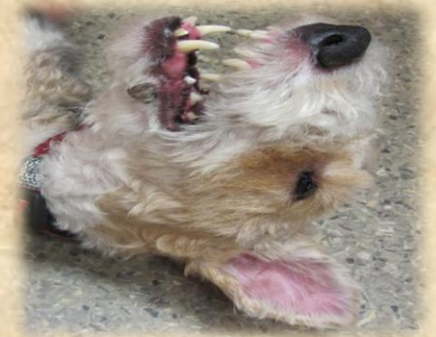

Felix again was discharged and back at his Rescue Home. He was not a happy camper for the cone or any apparatus for assistance. He was on Hydromorphone and an anti-inflammatory and gets supervised outside time. He enjoys laying on the rug on the deck on a nice day. The surgery was very traumatic for Felix and he is guarded and slowly trusting once again.



On August 28, 2013 Felix went to All Pets Hospital for a checkup of the surgery site, stitch removal (compliments of Felix) and to discuss the dental surgery with Dr. Navin. On August 29, 2013 Felix returned for his Dental Surgery. His teeth are misaligned & the upper canine conflicted with the lower and forced the canine to the outside & puncture a large hole in his gum. Both teeth needed extracting. 30 minutes is normal for canine removal but his pulled right out as it was so infected.

At the end of the root canal was filled with pus and is on the top of the snout and into the nasal canal. After the luxating patella surgery, it was noted several blood droplets in Felix's cone and most likely the cause due to the infection of this canine tooth. A lower front small tooth which was loose was also extracted.



Before the dental surgery you can see the large scabbed over hole in his lower gum. This was filled with bacteria & gunk. After the surgery, the hole was cleaned out and has healed rather quickly.



Another unfortunate discovery was made during dental surgery. Felix has arthritis in the jaw joint and cannot fully open and extend his mouth. This can occur from a mouth not functioning properly, inflammation or bacterial causes. Yet another painful condition that could have been avoided and Felix did not have to suffer with.

## **SURGERY SETBACK**

On the evening prior to Felix's dental surgery, a small silver dot was noticed on his left rear leg. A quick touch revealed this was metal and appeared to be a pin. During luxating patella surgery, pins which resemble brad nails are driven in to hold the patella in place and usually two are inserted. The plan was to inform the vet first thing in the morning on arrival.

However that morning - the pin was now missing and there was a tiny dot hole left on his leg. An x-ray taken of Felix's leg during dental surgery confirmed that one of the pins had migrated out and the other looked loose. Initial search of his bed and room could not locate this pin but later in the day it was found in a grout crack. Whew! At 7 p.m. the surgeon was phoned and an appointment for Felix set with Veterinary Special Center was for 9:00 a.m. Friday.



Felix was examined by Doctor Robbins who reviewed the forwarded x-ray which. The leg will need to be reopened and pins replaced.

From the morning the pin had migrated out of his leg, Felix was not putting any weight at all on that left leg and with the right leg virtually useless, this was a setback for him. The hole where the pin had escaped was a little oozy and the doctor felt it better to wait as Felix was on Clavamox rather than open up the site and allow infection to entire inside.

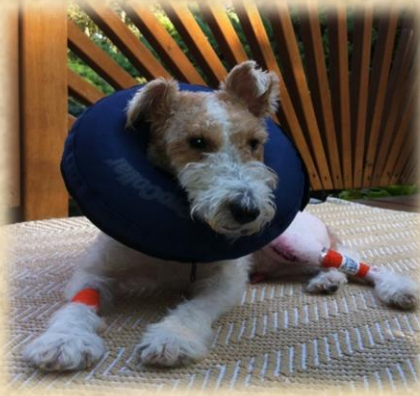

Felix returned to VSC on Tuesday, September 3rd and the surgery was performed. The pin replacement went well and he now has 3 pins in his rear left leg. Felix spent a few days on pain management and under observation & was released on September 5th.



Felix is a very smart and stubborn Wire Fox. After his exam at VSC, a soft cone was placed on him to prevent licking the site where the pin migrated out. As usual he was not pleased and was angry when arriving home - raising his voice and refusing to get out of the car. Prepared his food and upon delivery and looking through the glass doors to his private suite - the cone was off and laying on the floor next to his dog bed. Felix was lounging in his bed glaring giving his best evil eye. He is determined to do things Felix's way.

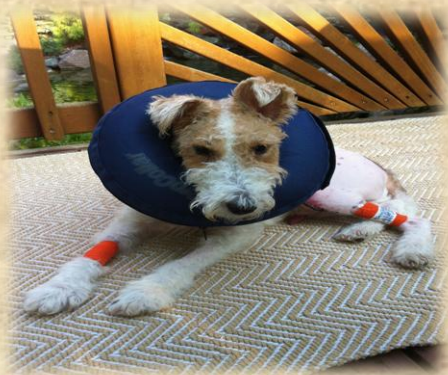Felix is not utilizing the leg as much as hoped and he still puts most of his weight on the front legs.



The bandages and Fentanyl Patch were removed, another delicate procedure approaching him at his hang out on the rug, rubbing him and the quick muzzle. His appetite comes and goes and taking it a day at a time.



Felix still believes his right deformed leg can be used as a paddle to aid his left leg. He brings his posture down to the level of the right which then causes him to use the left in a bent fashion. A rehab program was designed to help heal the surgery leg and teach him to use this leg properly.



## THERAPY & REHAB

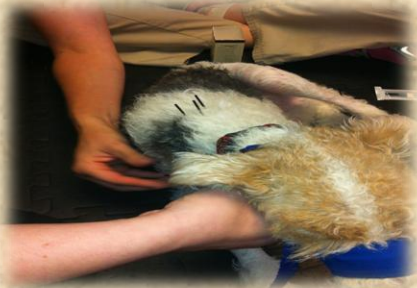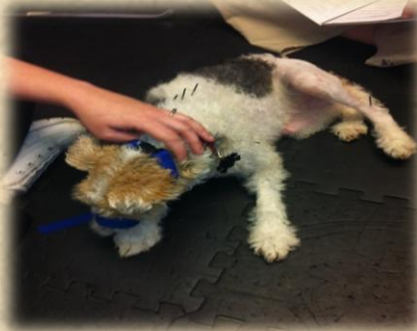Felix had his rehabilitation evaluation with Integrative Pet Care on September 12, 2013. He has muscle loss in his left leg and the leg is very tight. The need for him to extend and stretch that leg is imperative to his recovery. The right rear leg which is beyond repair has severe contracture and the muscles have fused together.

After his pin replacement surgery, the inflatable donut collar was given a try for Felix and it proved to be the best out of the four devices used. He was caught manipulating his leg around the donut to lick the stitches.



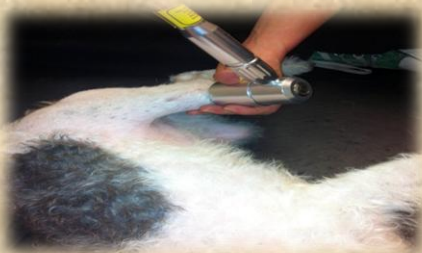## Felix's Therapy Program:

Ultra Sound Therapy which will loosen his tight muscles and allow him to stretch and flex his leg into a straight position. Felix gets totally relaxed during this treatment as it feels so good.



Massages to ease tension and tightness in his back muscles and reduce the kyphosis.

Laser Therapy is the use of light to stimulate biological processes that lead to faster healing and pain relief. The cells in the area receiving the light absorb the light energy, which stimulates the body to release anti-inflammatory chemical compounds.

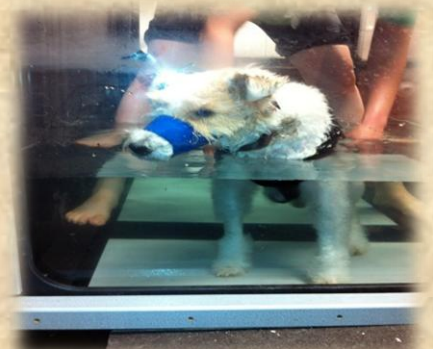

The physical exercises help retrain his habits and teach him to put more weight and pressure on that left leg.

Acupuncture which is the stimulation of specific points on the body has been very beneficial for his kyphosis of the spine.



Felix started Phase II of his Therapy Program. A DogLeggs' Vest with Ehmer Sling was ordered & arrived for Felix. His deformed right leg will be held up and aid in him using the left leg standing up straight and putting full weight on and not bring his posture down to use the right.



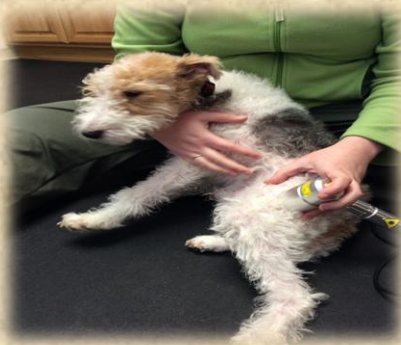Felix started Water Treadmill Therapy with his new Sling. He was unsure what to expect his first week but like most Wire Fox Terriers is now advanced the routine. The water level is adjusted depending on the difficulty each session.

The buoyancy of the water takes the pressure off the joints and especially his overburdened front legs and gets him moving that rear left leg in a straighter position and placing more pressure down.



Felix has made tremendous progress through therapy. His right leg which he used to paddle to the side he now holds up. His left leg has built muscle mass and has gotten straighter and stronger.

Felix had some bumps in the road in December of 2013 when allergies flared up with yellow crusts and pustules from lower torso on up. His treadmill therapy was postponed to determine if the chlorinated water was a factor or other topical chemical or shampoo.



Felix continues with Laser Therapy and occasional acupuncture as there is a noticeable benefit with his kyphosis and legs.

The arthritis in his jaw joint as well as inflammation flares up and cranky Felix surfaces as well as soreness and he is on 25 mg of Rimadyl which does help him greatly.



Felix is also referred to as Feefers, a nickname bestowed upon him during his journey.

A donated doggie stroller was converted into a Feefer Mobile which is lower to the ground and gives him the feeling of floating while on the lookout for chipmunks and critters.



Felix is on alert when outside and his obsession started with the koi pond staring at them from his vantage point on the deck. Oooh those darn fishies really get him so excited. Felix has gone for walks to visit the pond and there is no hesitation on his part to want to jump right in!

