

# NOELLE

## Cardiology Care Package

Noelle was born October 12, 2013 with genetic malformations of the heart. She was diagnosed with a Grade IV Heart Murmur on arrival at WFTRM. On December 23, 2013 she had a full cardiology evaluation performed at Chicago Veterinary Specialists and diagnosed with Severe Pulmonic Stenosis. It was recommended she be evaluated for a balloon valvuloplasty procedure at Purdue University.



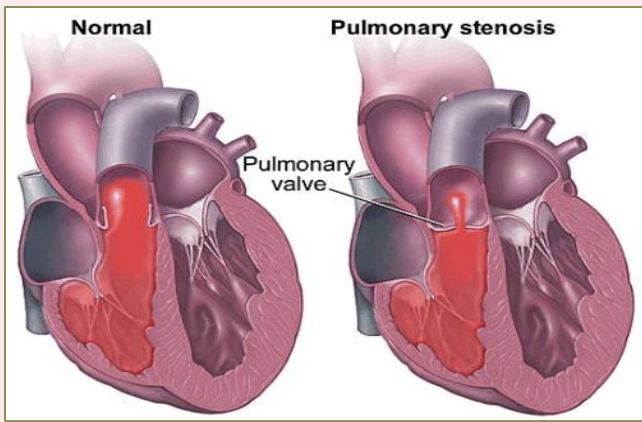
*After the diagnosis of pulmonic stenosis is made, the next most important issue is to grade its severity. This is done with a type of ultrasound called Continuous Wave Doppler Echocardiography. A pressure gradient across the pulmonic valve can actually be measured in units called millimeters of mercury (mm of Hg.) A pressure gradient of less than 40 mm of Hg generally requires no treatment at all. A gradient greater than 80 mm of Hg have a significant risk of sudden death and therapy should be pursued (generally balloon valvuloplasty).*



**Noelle's  
pressure  
gradient on  
12/23/13  
was 100.**

*In pulmonic stenosis, the right ventricular outflow tract is narrowed either at the actual valve, just before it, or just after it. The most common form of pulmonic stenosis involves a deformed pulmonary valve such that the valve leaflets are too thick, the opening is too narrow, or the valve cusps are fused. The heart must pump extra hard to get the blood through this unusually narrow, stiff little valve. The right side of the heart becomes thick from all this extra work but in doing so its normal electrical conduction may not be normal. The rhythm of the heart's filling and pumping cycle can be disturbed as the muscle becomes abnormal.*

*If the obstruction at the pulmonic valve could be relieved, much of the problem would be solved. Severe pulmonic stenosis cases can be treated by doing just that. A special balloon is inserted into the pulmonic valve where it is inflated, breaking down the obstruction. The size of the balloon catheter is determined by echocardiography as described above. Dogs that have pressure gradients of greater than 80 mm Hg across the pulmonic valve should have this procedure regardless of whether or not they are showing clinical signs. Dogs with concurrent tricuspid valve dysplasia benefit from this procedure regardless of their pressure gradient.*



*Performing a balloon valvuloplasty reduces the risk of sudden death by 53% and improves quality of life as well. Dogs for whom the stenosis is just before the valve rather than at the valve itself may benefit from surgery.*

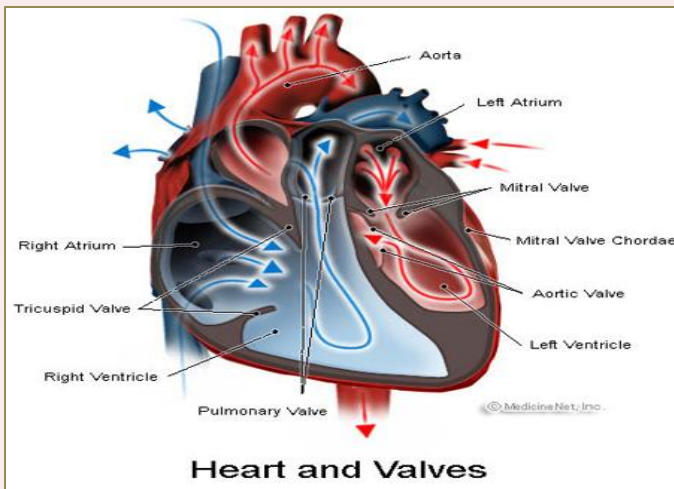
Noelle travelled to Purdue University on Tuesday, January 14, 2014. She was to be evaluated with more testing and the balloon valvuloplasty surgery performed on January 15.



Noelle wore her little red parka for the long and very cold road trip to Purdue.

Noelle's blood work, heart rate, temp and respiratory rate were all normal. The echocardiogram performed on January 15, 2014 revealed that Noelle had subvalvular pulmonic stenosis which is the narrowing of the right ventricle below the pulmonic valve. The level of stenosis results in a dual chamber right ventricle. There was also leakage at the tricuspid valve.

During Noelle's surgery on the 15<sup>th</sup>, the catheter enters the tricuspid valve and must travel up to the pulmonary valve. Her stenosis is located under the pulmonary valve and the catheter was unable to be passed through the stenotic area. While attempting to place the catheter through this area, there was extrusion outside the cardiac chambers in effusion of blood around the heart. No further attempts could be made and the procedure stopped. Noelle recovered from anesthesia and was monitored in ICU that evening.



*There is no complete cure for pulmonic stenosis. Unfortunately, medication for pulmonic stenosis is only helpful to manage any right-sided heart failure. In some cases, medications called beta blockers can be used in an attempt to relax the muscles of the heart and dilate the stenosis.*

*[Pulmonic Stenosis - Veterinary Partner Library]*

Noelle is on a beta blocker which she will continue to take for at least a year. She is on Atenolol 5mg oral suspension twice a day. This dosage will need to be adjusted as she grows and eventually can be administered in pill form.



On January 16 an echocardiogram was performed and there was no fluid around her heart. Noelle's pressures had reduced to 55 mmHg from before surgery of 143 mmHg. This is significant pressure drop and the outcome hopefully looking to achieve had the entire balloon procedure been performed. The test will be a one month echocardiogram whether this break in the stenotic area remains open. The leakage at the tricuspid valve, however has mildly increased from pre-procedure. (01/16/14 Cardiology Discharge Report)



The long term response to pulmonic stenosis is difficult to predict in individual patients with some affected living good quality, long life spans despite the presence of severe stenosis and other dogs with only moderate stenosis developing signs of CHF at a young age. (12/23/13 Cardiology Report)